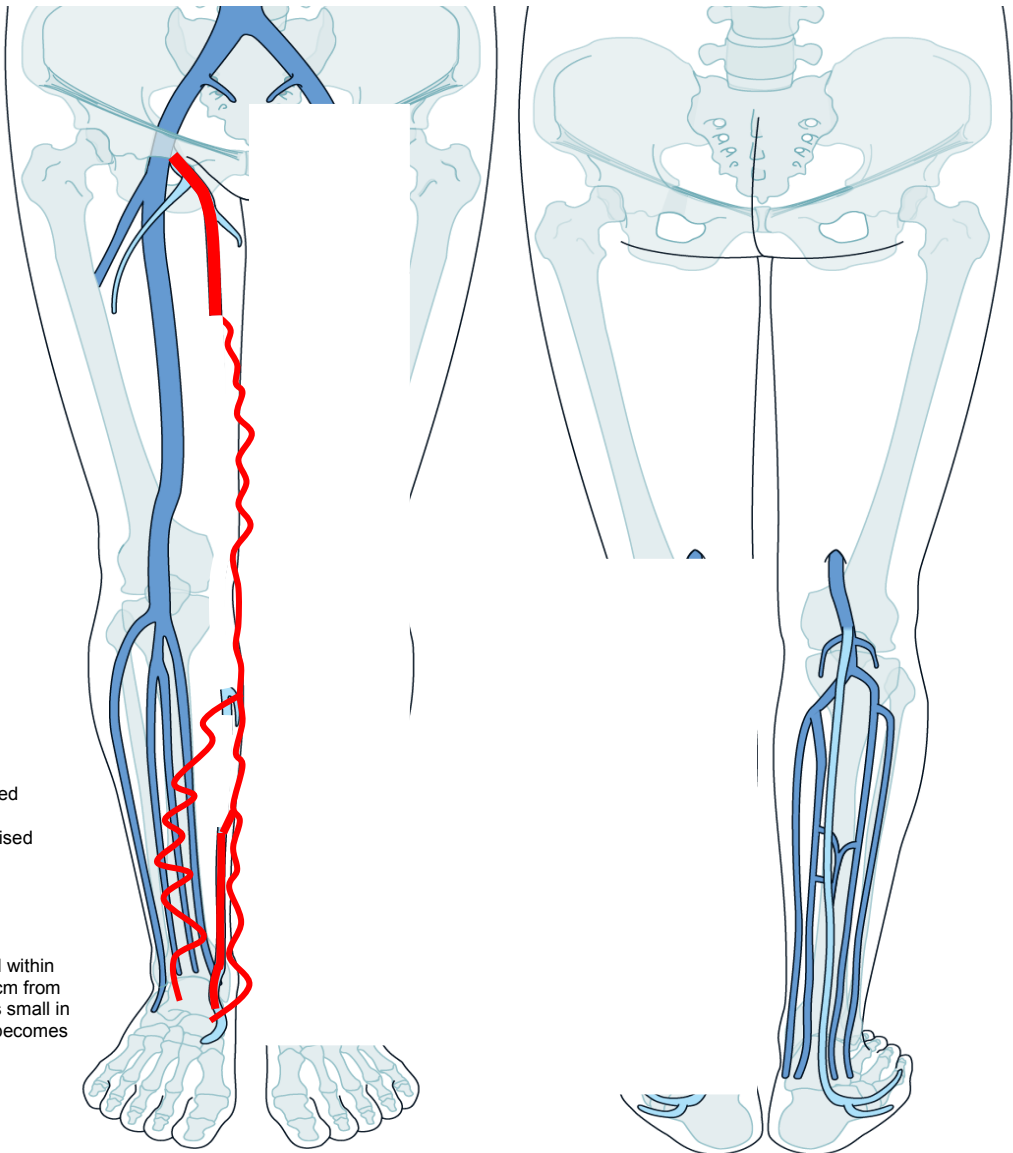


Vascular lab report

Assessed by: Suleman Choudhury

Anterior view

Posterior view



Right GSV:

Proximal thigh – 7mm
Mid-thigh – 1mm
Distal thigh – Not visualised

Proximal calf – Not visualised
Mid-calf – Not visualised
Distal calf – 4mm

The GSV lies straight and within the fascia in the initial 10cm from its origin. It then becomes small in diameter and eventually becomes untraceable.

red colour denotes reflux Competent superficial vein Competent deep vein Deep vein scarring

US Doppler lower limb veins Rt:

The Sapheno-Femoral Junction (SFJ) and Greater Saphenous vein (GSV) are patent and incompetent. The GSV fills a varicose vein (8mm) in the proximal thigh which courses medially into the foot as well as across the knee into the lateral aspect of the foot.

The Sapheno-Popliteal Junction (SPJ) and Short Saphenous vein (SSV) are patent and competent.

All deep veins are all patent and competent.

No incompetent perforators detected.
